

Malignant Melanoma of Anorectum with Liver Metastasis: A Case Report

Sumit Gupta¹, Anil Sarolkar², Amit Varma³, Virendra Bhandari⁴

Author's Affiliation: ¹Registrar, ²Associate Professor, ³Professor, Department of Radiation Oncology, ⁴Professor, Department of Pathology, Sri Aurobindo Medical College & PG Institute, Indore, Madhya Pradesh 453555, India.

Corresponding Author: Anil Sarolkar, Professor, Department of Radiation Oncology, Sri Aurobindo Medical College & PG Institute, Indore, Madhya Pradesh 453555, India.

Email: virencancer@yahoo.co.in

Received on 17.06-2019, **Accepted on** 11.07.2019

Abstract

Anal melanoma is an uncommon and very aggressive cancer. Different surgical techniques have been used to manage this disease with no clear favour of one approach over the another. We saw one patient with a mass in anal region whose upper limit could not be reached on per rectal examination. Investigations and histopathology suggested it to be a locally advanced lesion with metastasis in liver. Extensive surgery was performed and then patient was advised chemotherapy but he did not took the treatment and was lost to follow up. We present this case because of rarity of the lesion and established form of treatment except role of surgery in early cases.

Keywords: Malignant Melanoma; Anal canal; Treatment.

How to cite this article:

Sumit Gupta, Anil Sarolkar, Amit Varma, Virendra Bhandari, *et al.* Malignant Melanoma of Anorectum with Liver Metastasis: A Case Report. Indian J Canc Educ Res. 2019;7(2):125-128.

Introduction

Anorectal malignant melanoma (AMM) is an uncommon and aggressive cancer with a bad prognosis.^{1,2} It accounts for 1–3% of all anal tumors and 0.3% of all melanoma.³ Incidence of malignant melanoma is 1.6% and total mortality rate 0.6%.⁴ It arises from melanocytes in the mucosa at the anorectal junction. It presents most frequently in the 5th to 6th decade of life with equal incidence in both sexes.³ It has a predilection for early infiltration and distant spread resulting in a poor survival. Surgical resection is the primary curative treatment while chemotherapy and radiotherapy has little role in its treatment. Prognosis of metastatic malignant melanoma is extremely poor. Life expectancy in patients with metastatic disease is between 6 to 9 months. The 5-year disease-free survival is seen in less than 20% of the patients treated.⁵⁻⁷ This case is reported as anal melanoma is one of the rare malignancy and presents with metastasis.

Case History

We report here a case of 58-year-old male who presented with complaint of mass protruding out through anus which was insidious in onset and associated with pain since 2 years and also had per rectal bleeding since last 1 year.

On examination there was an Ulceroproliferative growth felt at anal verge, the superior margin of the growth could not be reached. There was no other relevant clinical finding. Biopsy from anal canal growth was done on 10th November 18 which showed signs of Malignant Melanoma. CT scan whole abdomen and MRI Pelvis with screening of the chest was done on 23th December 18 which showed extensive polypoidal circumferential mural thickening in the lower portion of the rectum and anal canal, up to anal verge (Fig. 1). The length of segment involved measures 11.4 cm with maximum thickness of 64 mm. There was extension of the disease in right perianal space

and infiltration in the right anal sphincter with involvement of mesorectal fascia, predominantly along its anterior and right lateral aspect. Few discrete lymph nodes are seen in bilateral inguinal region (largest 13×12 cm), right external iliac, left external iliac likely metastatic. Liver reveals few sub-centimeter cystic lesions in both lobes likely metastatic. Patient then underwent abdominal perineal resection, liver metastectomy & bilateral inguinal node dissection. Postop HPE revealed large fungating gray black mass 9×8×7.5 cm with broad base seen in rectum and anal canal reaching

up to skin, infiltrating anal wall and rectal wall up to the serosal layer (Fig. 2). Lymphovascular invasion and perineural invasion are positive, all margins are free, right inguinal lymph node 3/17 positive for metastasis, left inguinal lymph node all 13 negative for metastasis, segment VI of liver shows metastatic tumor (Fig. 3). The final diagnosis is Malignant Melanoma of anorectum with metastasis to right inguinal lymph node and liver. The patient was advised to take further chemotherapy but he did not take any treatment and was lost to follow up.

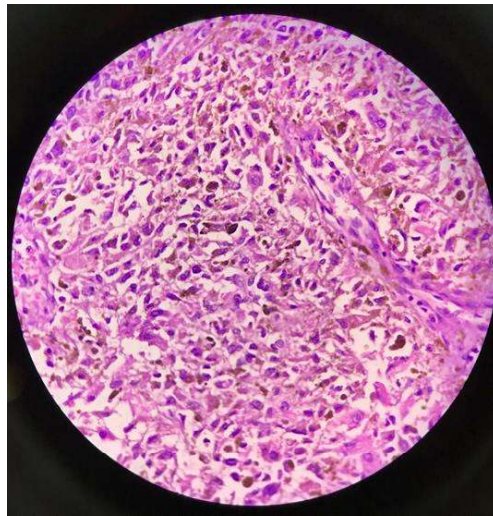


Fig. 1: Anal canal biopsy-Section show polygonal to spindle cells. Cells showing intracytoplasmic melanin pigment.

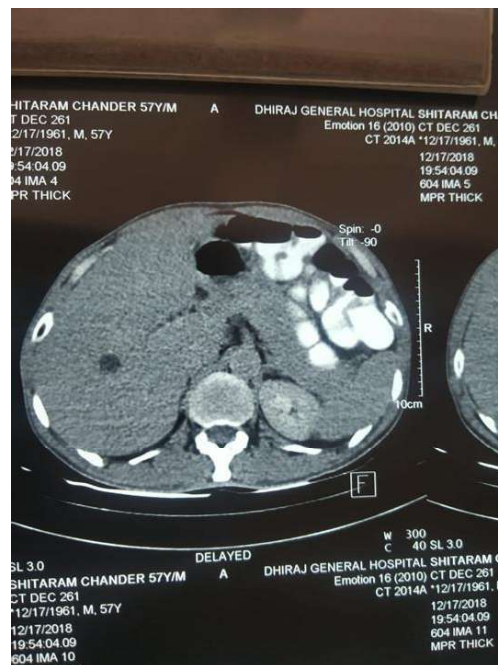


Fig. 2: CT scan shows lesion present in liver

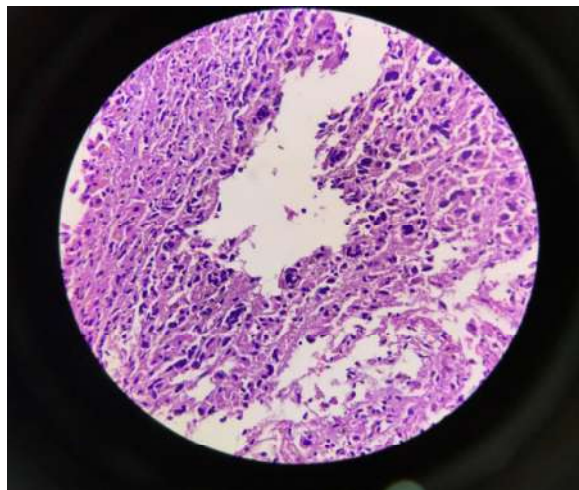


Fig. 3: Segment 6 liver biopsy show metastatic tumor

Discussion

In the year of 1857 first case of Anorectal melanoma was reported by Moore DW in 1857.⁸ Because of its rare incidence clinicians have lower suspicion of this disease and patient presents late. AMM can rarely metastasize to liver, lung, and brain.⁹ Anorectal melanoma is not easy to diagnose because of its unclear presentation. Each patient with AMM should be discussed in an interdisciplinary board and treatment should be based on the tumor size, age, comorbidities, and absence or presence of metastases. Surgical resection is the mainstay of treatment.^{1,10,11} APR with or without bilateral inguinal lymphadenectomy and wide local excision (WLE) have been used to manage patients with AMM. Chemotherapy has little response and radiotherapy has no benefit.¹² A recent article in literature has shown that the survival rate of patients with anal melanoma is similar after local excision or rectal resection, irrespective of whether localized or regional disease.¹³ Adjuvant radiation therapy is very well tolerated and is promising in improving loco regional control.¹⁴ Prognostic factors to help survival are also not clear; nevertheless, there is a strong association between stage of disease and microscopic perineal invasion. Of all the patients diagnosed with anorectal melanoma, 5-year survival rate is less than 20%.⁵⁻⁷

Conclusion

In the presented case, AMM was diagnosed after biopsy from the anal growth. After confirmation and metastatic workup performed. Despite aggressive

surgical management, disease progression was very rapid; with the development of hepatic metastases within 5 months. This case demonstrates the aggressive nature of AMM. The incidence and mortality from AMM are increasing now and there is no effective treatment for the disseminated disease. Therefore, until more evidence becomes available, the quality of life must be kept in focus when managing AMM.

Sources of support: NIL

Ethical Issues: NIL

Conflicting Interest: NIL

References

1. Podnos YD, Tsai NC, Smith D, Ellenhorn J D. Factors affecting survival in patients with anal melanoma. *Am Surg.* 2006;72(10):917-920.
2. Stroh C, Manger T. Primary amelanotic anorectal melanoma –A case report. *Zentralbl für allg. Pathol. Anat.* 2007;132:560-563.
3. Stefanou A, Nalamati SPM. Anorectal Melanoma. *Clin Colon Rectal Surg.* 2011 Sep;24(3):171-6
4. Bray F, Ferlay J, Soerjomataram I, *et al.* Global cancer statistics 2018: GLOBOCAN estimates of incidence and mortality worldwide for 36 cancers in 185 countries. *CA Cancer J Clin.* 2018 Nov;68(6):394-424.
5. Malaguarnera G, Madeddu R, Catania VE, *et al.* Anorectal mucosal melanoma. *Oncotarget.* 2018 Feb 2;9(9):8785-800.
6. Coventry BJ, Baume D, Lilly C. Long-term survival in advanced melanoma patients

- using repeated therapies: successive immunomodulation improving the odds. *Cancer Management and Research*. 2015;7:93-103.
7. Sandru A, Voinea S, Panaitescu E. Survival rates of patients with metastatic malignant melanoma. *J Med Life*. 2014 Oct-Dec;7(4):572-76.
 8. Buissin D, Sterle A, Schmiegelow P, *et al.* Primary anorectal malignant melanoma: a rare but aggressive tumor: report of a case. *World J Surg Oncol*. 2015;13:12.
 9. Singer M, Mutch M G. Anal melanoma. *Clin Colon Rectal Surg*. 2006;19(2):78-87.
 10. Pessaux P, Pocard M, Elias D, *et al.* Surgical management of primary anorectal melanoma. *Br J Surg*. 2004;91:1183-7.
 11. Mason JK, Helwig EB. Ano-rectal melanoma. *Cancer*. 1966;19:39-50.
 12. Moozar KL, Wong CS, Couture J. Anorectal malignant melanoma: treatment with surgery or radiation therapy, or both. *Can J Surg*. 2003 Oct;46(5):345-49
 13. Kiran RP, Rottoli M, Pokala N, *et al.* Long-term outcomes after local excision and radical surgery for anal melanoma: data from a population database. *Dis Colon Rectum*. 2010;53:402-8
 14. Homsji J, Garrett C. Melanoma of the anal canal: a case series. *Dis Colon Rectum*. 2007;50:1004-10.
-